Available online at www.sciencedirect.com
ScienceDirect
Biomaterials 29 (2008) 2249–2258
Biomaterials
www.elsevier.com/locate/biomaterials

Effect of β-tricalcium phosphate particles with varying porosity on osteogenesis after sinus floor augmentation in humans

Christine Knabe [a,*], Christian Koch [a], Alexander Rack [b,c], Michael Stiller [d]

[a] Department of Experimental Dentistry, Campus Benjamin Franklin, Charité – University Medical Center Berlin, Aßmannshauser Strasse 4-6, D-14197 Berlin, Germany
[b] Helmholtz Research Center, Karlsruhe, Germany
[c] Hahn Meitner Institute, Berlin, Germany
[d] Department of Plastic and Maxillofacial Surgery, Division of Oral Surgery, Charité – University Medical Center Berlin, Campus Benjamin Franklin, Aßmannshauser Strasse 4-6, D-14197 Berlin, Germany

Received 19 December 2007; accepted 28 January 2008
Available online 19 February 2008

Abstract

This study examines the effect of two β-tricalcium phosphate (TCP) particulate bone grafting materials with varying porosity on bone formation and on osteogenic marker expression 6 months after sinus floor augmentation. Unilateral sinus grafting was performed in 20 patients using a combination (4:1 ratio) of β-TCP particles with 35% porosity (TCP-C) or 65% porosity (TCP-CM) and autogenous bone chips. At implant placement cylindrical biopsies were sampled and processed for immunohistochemical analysis of resin embedded sections. Sections were stained for collagen type I (Col I), alkaline phosphatase (ALP), osteocalcin (OC) and bone sialoprotein (BSP). Furthermore, the area fraction of newly formed bone as well as the particle area fraction were determined histomorphometrically first, apically close to the Schneiderian membrane and second, in the center of the cylindrical biopsies. In the TCP-CM patient group a larger amount of bone formation and particle degradation was observed in the apical area and thus at the largest distance from the crestal bone compared to the TCP-C group. Good bone bonding behaviour was observed with both materials. This was accompanied by expression of ALP, Col I, BSP and OC in the newly formed bone and osteogenic mesenchym in contact with the degrading particles. Both TCP materials supported bone formation in the augmented sinus floor. Six months after implantation of both types of β-TCP particles, bone formation and matrix mineralization was still actively progressing in the tissue surrounding the particles. Consequently, a greater porosity appears to be advantageous for enhancing bone formation and particle degradation.

Keywords: Bone substitute materials; Tricalcium phosphate ceramics; Porosity; *In vivo*; Osteoblast differentiation; Hard tissue histology

1. Introduction

The use of dental implants has become a common treatment to replace missing or lost teeth [1]. However, when teeth are missing, the natural resorptive process subsequent to extraction frequently results in an alveolar ridge with deficient bone volume [1,2]. Thus, augmentation of the alveolar ridge before implant placement is frequently required in implant dentistry [1–3].

The current gold standard for bone reconstruction in implant dentistry is using autogenous bone grafts [3,4]. Among the various techniques to reconstruct or enlarge a deficient alveolar ridge, augmentation of the maxillary sinus floor with autogenous bone grafts has become a well-established pre-implantology procedure for alveolar ridge augmentation of the posterior maxilla [4,5]. The main disadvantages of autogenous bone grafts have been the need for an additional surgical site, increased donor site morbidity, insufficient volume of (intraorally) harvested bone, and the need to use general anaesthesia for extraoral bone harvesting [4–7]. Using biodegradable bone substitutes would simplify sinus floor elevation procedures, since it avoids second-site surgery for

* Corresponding author. Tel.: +49 30 450 562 208; fax: +49 30 450 562 902.
E-mail address: christine.knabe@charite.de (C. Knabe).

0142-9612/$ - see front matter © 2008 Elsevier Ltd. All rights reserved.
doi:10.1016/j.biomaterials.2008.01.026

autograft harvesting [4–10]. In recent years, the use of tricalcium phosphate (TCP) particles as alloplastic bone graft materials for sinus floor elevation procedures has received increasing attention in implant dentistry [4,7–10]. More recently, the use of TCP particles with increased porosity has been promoted in order to increase the biodegradability [11,12]. These particles exhibit a material structure with micro-, meso- and macropores, which is designed to enhance the degradation process. This structure allows for a reduced bulk density. The microporosity allows circulation of biological fluids, increases the specific surface area and thus accelerates the degradation process. The interconnectivity of the pores creates a capillary force that actively draws cells and nutrients in the center of the particles. The macroporosity is created to encourage the ingrowth of bone by permitting penetration of cells and vascularization [11].

Ideally, a bone substitute material for alveolar ridge augmentation should resorb rapidly, but still stimulate osteogenesis at the same time [4,5]. This in turn requires the ability to activate bone formation and, thus, cause the differentiation of osteoprogenitor cells into osteoblasts at its surface [13]. Therefore in order to evaluate the osteogenic potential of bioactive ceramics for bone regeneration it is important to examine the effect of these materials on osteoblastic differentiation [13–15]. Histological evaluation of the bone–biomaterial interface requires undecalcified polymethylmethacrylate (PMMA) sections [16]. While various assays have been developed which permit studying the effect of biomaterials on the expression of osteogenic markers *in vitro* [13–15,17,18], there have been considerable difficulties to visualize the expression of these markers in undecalcified implant material containing sections of bone obtained from *in vivo* studies. Methylmethacrylate (MMA), the resin of choice for undecalcified bone histology, can only be used for bone enzyme and immunohistochemistry, if the usual highly exothermic polymerization procedure is avoided, which destroys both, enzyme activity and tissue antigenicity. Paraffin, the standard embedding medium for bone enzyme and immunohistochemistry, can only be used for demineralized tissue, which does not contain ceramic or metal implant materials. To avoid these difficulties Neo and coworkers [19,20] performed *in situ* hybridization on decalcified sections of bone using procollagen I ($\alpha 1$) and osteonectin, osteocalcin and osteopontin probes to analyze the tissue response around TCP particles at a molecular level by visualizing active osteoblasts in their different stages of differentiation [19,20]. This implied, however, that the implant material had to be removed from the specimens during the decalcification process.

Only recently have low temperature embedding resins with improved tissue antigenicity preservation and respective embedding techniques become available that permit immunohistochemical analysis on resin embedded hard tissue sections [16]. Moreover, we have been able to develop a new technique that facilitates immunohistochemical analysis of osteogenic markers on undecalcified sawed sections of bone. This methodology renders it possible to study the effect of ceramic bone substitute materials on osteoblast differentiation in *ex vivo* specimens by visualizing active osteoblasts in their different stages of differentiation [21].

In the current study the effect of two particulate TCP graft materials (porosity 35% and 65%, respectively) on bone regeneration and expression of an array of osteogenic markers was evaluated in biopsies sampled 6 months after augmentation of the sinus floor. This was in addition to examining the biodegradability.

2. Materials and methods

2.1. Patient selection

The study consisted of 20 patients (12 women and 8 men) ranging in age from 35 to 75 years (mean 57.8). The patients chosen were partially edentulous in the post-canine region. In all patients augmentation of the sinus floor was required in order to facilitate dental implant placement in the posterior maxilla. After routine oral and physical examinations, the patients were selected and sinus floor augmentation procedures were planned. The patients' data are listed in Table 1. Patients were excluded from research, if their health was compromised (ASA (III or IV) – American Society of Anesthesiology) and if they were suffering from any drug abuse, including alcohol, or any significant systemic disease. All patients had good oral health and no active periodontitis. Patients selected were non-smokers or had stopped smoking at least 6 months prior to the first surgery. All patients were fully informed about the procedures, including the surgery, bone substitute materials and implants. They were asked for their cooperation during treatment and research; all gave their informed consent. The study was performed in accordance with ethic protocols approved at the Charité University Medical Center.

2.2. Radiographs and Digitized Volumetric Tomography

Routine panoramic radiographs were obtained in all cases pre- and postoperatively, 6 months after the first surgery (prior to implant placement), and immediately after implant placement. In addition, Digital Volumetric Tomography, NewTom™, Italy was used in all patients to assess sinus floor anatomy and bone volume preoperatively.

Table 1
Patient data

	Patient	Age (years)	Gender	Bone substitute material
1	B.M.	43	F	TCP-C
2	G.A.	67	M	TCP-C
3	U.B.	61	F	TCP-C
4	E.W.	64	M	TCP-C
5	W.K.	63	M	TCP-C
6	A.Sch.	60	F	TCP-C
7	S.H.	50	F	TCP-C
8	M.B.	71	F	TCP-C
9	B.St.	35	M	TCP-C
10	E.St.	50	F	TCP-C
11	M.B.	47	F	TCP-CM
12	R.Sch.	43	F	TCP-CM
13	R.M.	60	M	TCP-CM
14	H-J.D.	55	M	TCP-CM
15	P.M.	65	M	TCP-CM
16	I.L.	75	F	TCP-CM
17	R.M.	60	F	TCP-CM
18	A.L.	67	F	TCP-CM
19	Ch.L.	64	F	TCP-CM
20	J.B.	66	M	TCP-CM

TCP, tricalcium phosphate; TCP-C, Cerasorb; TCP-CM, Cerasorb M.

2.3. Sinus floor augmentation surgery

Patients were given antibiotic prophylaxis prior to sinus floor augmentation surgery (600 mg clindamycine, 2 h preoperatively). In all patients surgery was performed under local anaesthesia. Since the residual alveolus was 1–3 mm in height, a staged approach was used. The augmentation was then carried out according to Tatum [22]. The space created between the maxillary alveolar process and the new sinus was filled using a combination (4:1 ratio) of β-TCP particles and autogenous bone chips. The TCP particles used were globular particles of 1000–2000 μm grain size with 35% porosity (material denominated TCP-C) or polygonal particles of the same size with 65% porosity (material denominated TCP-CM) (Cerasorb M®, Curasan, Germany). Fabrication and material properties of these TCP particles have been described in detail previously [11]. The bone chips were harvested from the posterior surface of the maxilla (tuber maxillae) using a chisel. The TCP graft material (2 cm^3) was mixed with venous blood prior to delivery into the open sinus cavity. No perforations of the Schneiderian membrane occurred in any of the patients. A collagen membrane (BioGide™, Geistlich, Switzerland) was used to cover the access window to the sinus and complete wound closure followed. The following postoperative regime was applied to avoid infection: Clindamycine (Clindamycine Ratiopharm™, Germany) 1200–1800 mg daily for 7 days and intravenous administration of Cortison 250 mg (Soludecortin Merck™, Germany) in combination with oral administration of ibuprofen 800–1200 mg (IBU akut 400 Ratiopharm®, Germany) daily to reduce pain and swelling.

2.4. Dental implant surgery and biopsy retrieval

After 6 months of healing, the patients received implants. Dental implant placement and biopsy installation were carried out under local anaesthesia. Vertical incisions were made in the buccal mucosa distally of the canines and connected with a horizontal incision at the top of the alveolar crest. Bone was inspected and biopsies were taken with a 3.5 mm (outer) diameter trephine burr (inner diameter 2.75 mm) (Dentsply-Friadent, Germany) at the dental implant sites of approximately 10 mm depth, with copious irrigation with sterile saline. One or two biopsies (width 2.75 m) were harvested from each sinus at the site were dental implants would be placed. The biopsies were used for histologic, histomorphometric and immunohistological evaluation. If several implants were placed, then the site with the least previously existing bone height was chosen for histomorphometric evaluation. After biopsy specimen removal, osteotomy sites were prepared for implant placement and one of the following full body screw dental implants (Ankylos™, Dentsply-Friadent, Germany; Camlog™, Altatec, Germany; ITI™ Straumann, Switzerland) was placed in the implant bed with considerable care. This was followed by wound closure and the implants were allowed to heal subgingivally for 5 months.

2.5. Histology, histomorphometry and immunohistochemistry

The bone biopsy samples contained both the grafted area and the previously existing area of the sinus floor but the residual native crest was not included in the histologic and histomorphometric evaluation. The bone specimens were processed using a novel technique which facilitated performing immunohistochemical analysis on undecalcified hard tissue sections as described previously [21]. In brief, the tissue samples were immediately fixed in an ethanol-based fixative Neofix® (Merck, Germany) in order to maintain adequate antigenicity of the tissue. The biopsies were then embedded in a resin, which was composed of pure methylmethacrylate and *n*-butyl-methacrylate to which benzoyl peroxide and polyethylene glycol 400 *N*,*N*-dimethyl-*p*-toluidine (Merck, Germany) were added. After polymerization the blocks were glued to acrylic slides (Plexiglas GS209) (Röhm, Germany) using an epoxy resin based two-component adhesive (UHU, Germany). Sections (50 μm) were cut using a Leitz 1600 sawing microtome (Leitz, Germany) and then ground and polished. Subsequent to deacrylation of the sections by immersion in toluene, xylene and acetone, immunohistochemical staining was performed using primary mouse monoclonal antibodies specific to alkaline phosphatase (ALP) (Sigma, U.S.A.) osteocalcin (OC) (Abcam, U.K.), and rabbit polyclonal antibodies against type I collagen (Col I) (LF-39) and bone sialoprotein (BSP) (LF-84) [23]. Nonimmunized mouse, and rabbit IgG (Chemicon, U.S.A.) were applied as negative controls. The latter ruled out the non-specific reactions of mouse and rabbit IgG to human tissues, as well as non-specific binding of the secondary antibodies and/or peroxidase labeled polymer to human tissues. Incubation with a peroxidase labeled dextran polymer conjugated to goat anti-mouse and anti-rabbit immunoglobulins (DAKO EnVision+™ Dual link System Peroxidase, DAKO, Denmark) followed and the colour was developed using a liquid 3-amino-9-ethylcarbazole (AEC) system (DAKO, Denmark). Mayer's hematoxylin was used as a counterstain, and Kaiser's glycerol gelatin (Merck, Germany) was utilized for mounting with coverslips.

Other sections were stained for Tartrate Resistant Acid Phosphatase (TRAP) activity to identify cells with osteoclastic activity using a prefabricated kit (Sigma, U.S.A.) which is based on the method described by Goldberg and Barka [24]. This procedure stains cells with TRAP activity red. Mayer's hematoxylin was used as a counterstain. Sections obtained from experimental fracture healing sites in Male Wistar rats were used as positive controls, since osteoclasts were known to be present.

Semi-quantitative analysis of the immunohistochemically stained sections was performed as described previously [25–27]. The stained sections were analyzed under the light microscope by two experienced investigators with both investigators blinded to the staining. The tissues were examined for antibody decoration of cellular and matrix components. The cellular components examined included fibroblasts, osteoblasts, osteocytes and osteoclasts. The matrix components included trabecular bone, osteoid seams, bone marrow spaces and fibrous matrices. All these histological components were identified on morphological grounds. A scoring system quantified the amount of staining observed using light microscopy. A score of (+++ [=5]), (++ [=4]), and (+ [=2]) corresponded to generalized strong, moderate or mild staining, whereas a score of (+++ [=4]), (++ [=3]), and (+ [=1]) corresponded to strong, moderate or mild staining in localized areas. A score of (0) correlated with no staining. The scores for the amount of staining of a given cellular or matrix component for a respective marker were averaged for the 10 patients treated with TCP-C and TCP-CM, respectively. This also included subjecting the individual scores to statistical analysis. An average score of 3.5–5 was evaluated as strong expression in the given patient group, whereas an average score of (2.3–3.4), (1–2.2), and (0.1–0.9) was assessed as moderate, mild and minimal expression.

Furthermore, histomorphometric analysis was performed on a pair of sections 150-μm apart. The sections were measured semiautomatically using a light microscope (Olympus, Germany) in combination with a digital camera (Colourview III) and SIS Analysis™ software (Olympus, Germany). To this end, a square area 6.25 mm^2 in size was defined in two areas of each sections: first apically close to the Schneiderian membrane and secondly in the center of the cylindrical biopsy (Fig. 1). In both of these square areas the surface area that consisted of newly formed bone, and the area that consisted of graft material were measured in mm^2 and the area fraction of newly formed bone as well as the area fraction of grafted material was analyzed as percentage of the total. Data from each pair of section were averaged. Box-and-whisker plots were used for graphic illustration.

2.6. Statistical analysis

The student's *t*-test was used to determine statistical significance. Values of $p < 0.05$ were considered significant.

3. Results

3.1. Clinical results

After sinus floor augmentation, no postoperative complications occurred in any of the patients. Normal wound healing was observed after both the first and the second operations (graft harvesting/sinus elevation and implant placement surgery). Six months after augmentation all patients had sufficient

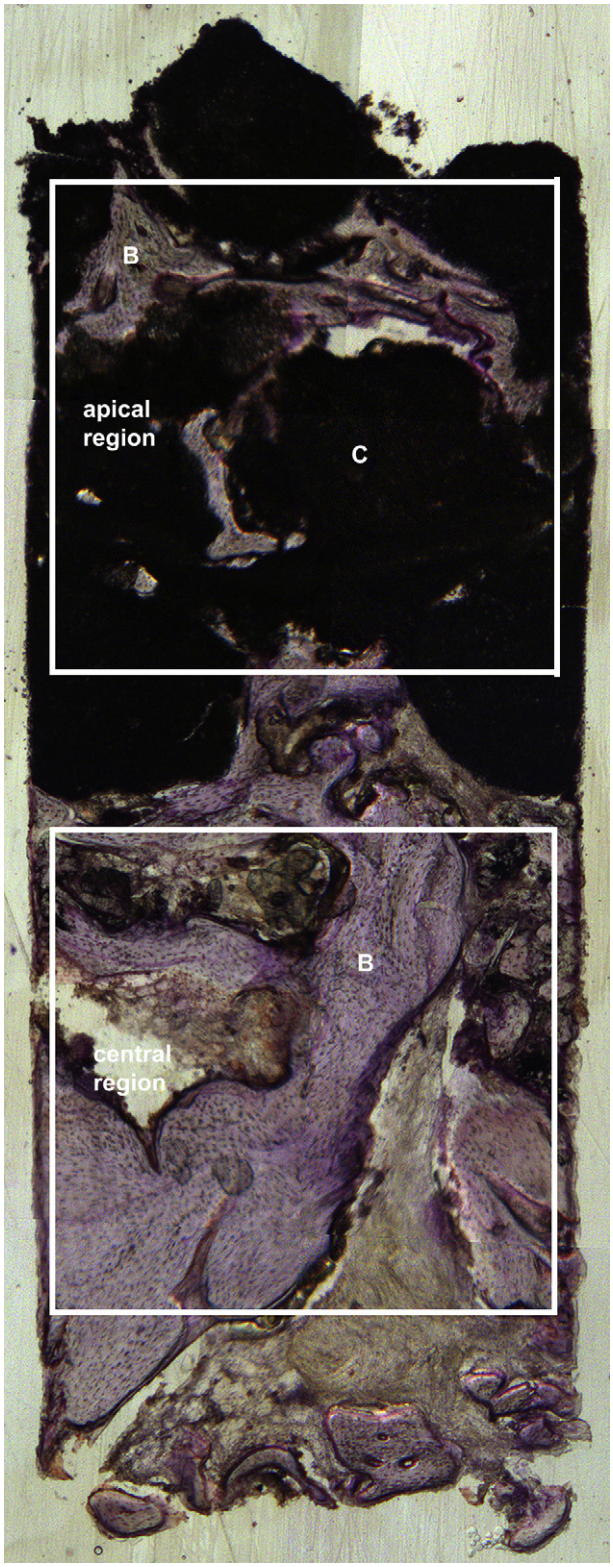

Fig. 1. Histomicrograph of biopsy sampled 6 months after augmentation of the sinus floor with tricalcium phosphate (TCP-C). Newly formed bone (B) and residual tricalcium phosphate particles (C) are visible. For the histomorphometric analysis a square area 6.25 mm^2 in size was defined in two areas of each sections: first apically close to the Schneiderian membrane and secondly in the center of the cylindrical biopsy. In both of these square areas the surface area that consisted of newly formed bone, and the area that consisted of graft material were measured in mm^2 and the area fraction of bone as well as the area fraction of grafted material was analyzed as percentage of the total. Undecalcified sawed section counterstained with hematoxylin (original magnification ×2).

bone levels for placement of the implants, with adequate primary stability. No implant failures were noted up to the time of the completion of this manuscript (2–3 years after implant placement). Biopsies varied in length between patients.

3.2. Histology, histomorphometry and immunohistochemical analysis

In the biopsies from the patients, in which TCP-C was used, the β-TCP graft material was present as achromatic rounded or scalloped granules, depending on the phase of resorption (Figs. 1–4). The granules were partially embedded in newly formed bone, which was predominantly lamellar bone. In the biopsies from the patients, in which TCP-CM was used, greater fragmentation of the β-TCP graft material was noted (Figs. 5–7) compared to the TCP-C material. With both TCP materials bone formation was preceded by the abundant proliferation of a cell rich-osteogenic mesenchym with positive expression of Col I, BSP and OC in cell and matrix components indicating progressing matrix mineralization (Figs. 2–7). Good bone bonding behaviour was observed with both materials as well as bone formation within the degrading particles, which was more advanced in the TCP-CM group (Figs. 2–7). This was accompanied by expression of Col I, ALP, BSP and OC in the newly formed bone in contact with both types of TCP particles (Figs. 2–7, Supplementary Tables A and B).

Fig. 8a and b demonstrate the results of the histomorphometric assessment. In the apical area close to the Schneiderian membrane the mean bone area fraction was $26.7 \pm 9.9\%$ and the mean particle area fraction was $42.3 \pm 14.6\%$ in the patient group, in which TCP-C was used as grafting material, whereas in the patients, in which TCP-CM was used, a mean bone area fraction of $35.5 \pm 12.3\%$ and a mean particle area fraction of $24.7 \pm 12.5\%$ were noted. In the central area of the biopsies, the mean bone area fraction recorded for the TCP-C group was $31.7 \pm 9.1\%$ and the mean particle area fraction was $13.7 \pm 11.6\%$. This corresponded to a mean bone area fraction of $40.3 \pm 11.1\%$ and a mean particle area fraction of $1.6 \pm 2.6\%$ in the TCP-CM group. Thus, in the TCP-CM group significantly more bone ($p < 0.004$) had formed in the apical area, (i.e. at the greatest distance from the original sinus floor) compared to the TCP-C group. This was associated with a significantly smaller amount of residual TCP grafting material ($p < 0.003$) being present in the TCP-CM group after 6 months of implantation. Also in the central area of the biopsies, a greater bone area fraction and a significantly smaller amount of TCP grafting material ($p < 0.03$) was recorded for the TCP-CM versus the TCP-C group. However, the difference in bone area was not statistically significant. In both groups, significantly smaller amounts of TCP grafting material ($p < 0.0005$ (TCP-CM); $p < 0.02$ (TCP-C)) were found in the

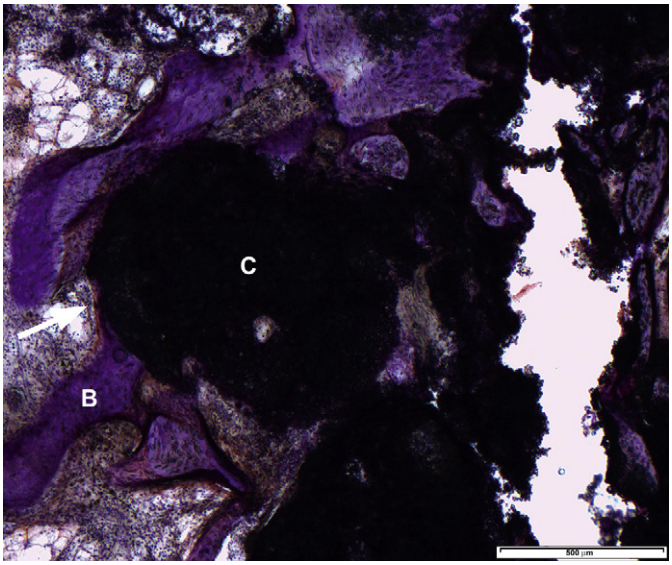

Fig. 2. Resin embedded biopsy stained immunohistochemically for osteocalcin after deacrylation. The biopsy was sampled 6 months after augmentation of the sinus floor with TCP-C (patient no. 7). Intense staining of the fibrous mesenchymal matrix lining the newly formed bony trabeculae (B) in contact with the TCP-C particle (C) is present (arrow). Undecalcified sawed section counterstained with hematoxylin. Bar = 500 μm.

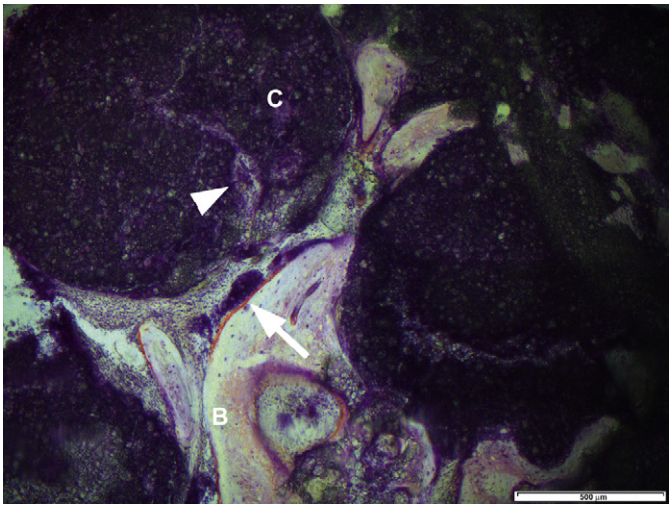

Fig. 4. Immunodetection of type I collagen in deacrylated sawed section of biopsy sampled 6 months after augmentation of the sinus floor with TCP-C (patient no. 3). Intense staining of the unmineralized fibrous matrix (of the osteogenic mesenchym) lining the newly formed bony trabeculae (B) in contact with the TCP-C particle (C) is present (arrow). Furthermore, beginning bone formation within the degrading particle is visible (arrowhead). Undecalcified sawed section counterstained with hematoxylin. Bar = 500 μm.

central portion of the biopses compared to the apical areas. Furthermore, a greater bone area fraction was measured in the central areas. These differences were not statistically significant, though.

Table 2 summarizes the results of the immunohistochemical analysis. In the TCP-CM patient group, moderate and thus more enhanced staining for osteocalcin (OC) was noted in the mineralized bone matrix compared to mild staining in the TCP-C patient group, while in the TCP-C group strong and thus more enhanced OC expression was observed in the unmineralized fibrous matrix of the cell rich-osteogenic mesenchym ($p < 0.011$) (Figs. 2,3 and 7). This is indicative that in the TCP-CM group bone formation and matrix mineralization had already reached a more advanced state, but were still progressing, while in the TCP-C group mineralization of the yet unmineralized fibrous matrix was strongly progressing at this stage. In addition, also BSP showed strong staining of the unmineralized fibrous matrix components both apically as well as centrally in the TCP-C group, while in the TCP-CM group moderate BSP expression was noted. These differences

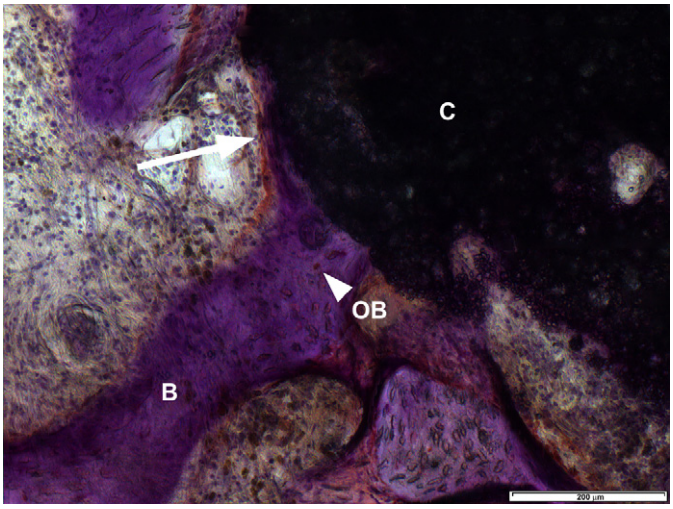

Fig. 3. Enlargement of Fig. 2. Intense staining of cells and unmineralized fibrous matrix (of the osteogenic mesenchym) lining the newly formed bony trabeculae (B) that are in contact with the TCP-C particle (C) is evident (arrow). OB (arrow head) – intensely stained osteoblast. Bar = 200 μm.

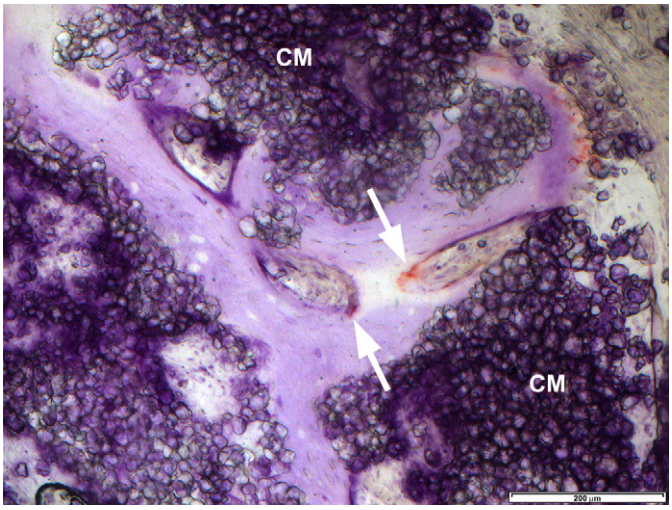

Fig. 5. Immunodetection of type I collagen in deacrylated section of biopsy sampled 6 months after augmentation of the sinus floor with TCP-CM (patient no. 16). Strong staining of cells and fibrous matrix lining the newly formed bone, which has formed within the degrading TCP-CM particles (CM), is present in localized areas (arrows). Undecalcified sawed section counterstained with hematoxylin. Bar = 200 μm.

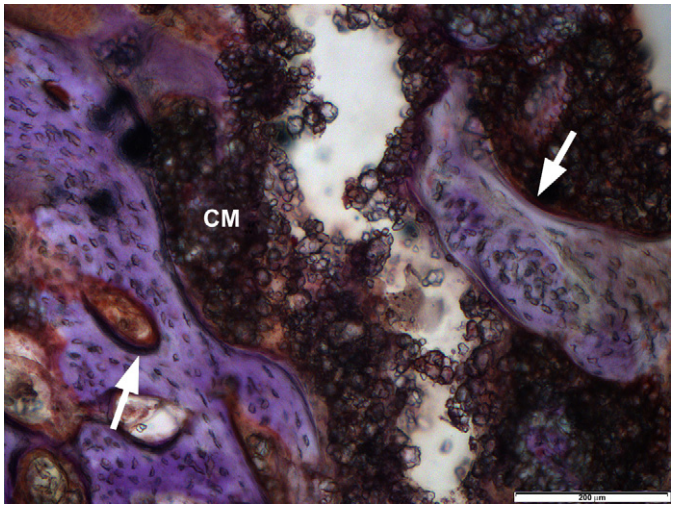

Fig. 6. Bone sialoprotein immunodetection in deacrylated section of biopsy sampled 6 months after augmentation of the sinus floor with TCP-CM (patient no. 15). Intense staining of the unmineralized fibrous mesenchymal matrix, cells and osteoid lining the newly formed bone, which has formed within the degrading TCP-CM (CM) particles, is visible (arrows). Bar = 200 µm.

were not statistically significant, however. This was accompanied by a slightly greater BSP expression in osteoblasts and fibroblasts in the apical area of the TCP-C specimens compared to TCP-CM samples (Fig. 6). In the TCP-CM group, mild and thus slightly stronger staining for ALP was noted in the mineralized bone matrix as well as in the fibrous matrix the of the cell rich-osteogenic mesenchym compared to minimal staining in the TCP-C group. In two patients of the TCP-C group, this was accompanied by mild to moderate staining in osteoblasts. In the TCP-CM group, Col I showed moderate

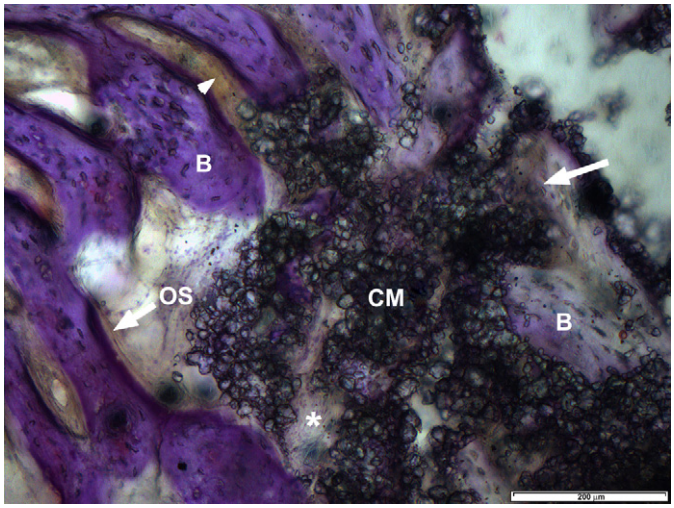

Fig. 7. Immunodetection of osteocalcin in deacrylated section of biopsy sampled 6 months after augmentation with TCP-CM (patient no. 19). Bone (B) formation within the degrading particles and mild staining of both the mineralized bone matrix (arrow) as well as of osteoid (OS) is present. This is in addition to moderate staining of the unmineralized fibrous mesenchym (arrowhead). Furthermore, areas of beginning woven bone formation are visible (asterisk). Bar = 200 µm.

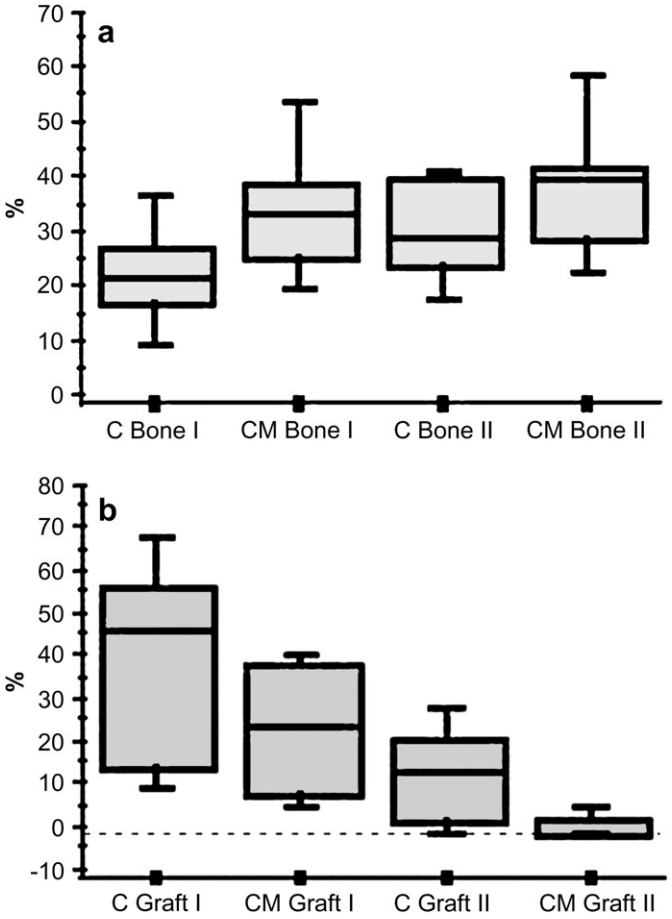

Fig. 8. (a) Box-and-Whiskers-Plot demonstrating the results of the histomorphometric evaluation of the area fraction of newly formed bone for TCP-C (C) and TCP-CM (CM) in the central (I) and apical (II) area of biopsies sampled from 10 patients each. The centerline indicates the median. Half of the scores are less than the median and half are larger than the median. The two ends of the box show the range within which the middle 50% of all measurements lie, and the whiskers indicate the range within which the middle 75% of all measurements lie. (b) Box-and-Whiskers-Plot demonstrating the results of the histomorphometric evaluation of the particle area fraction for TCP-C (C) and TCP-CM (CM) in the central (I) and apical (II) area of biopsies sampled from 10 patients each.

and thus stronger staining of both the mineralized bone matrix as well as of the fibrous matrix of the osteogenic mesenchym, compared to mild expression in the TCP-C group. This difference, however, was only statistically significant for the fibrous matrix in the central area of the sections. Furthermore, positive cellular staining for Col I was observed in both patient groups. In the TCP-C group, Col I expression in osteocytes was mild and thus slightly greater compared to the TCP-CM group. The positive expression of these bone matrix proteins indicates that 6 months after augmentation of the sinus floor, bone matrix synthesis and matrix mineralization, and thus bone formation, were still actively progressing in both patient groups. All sections stained for nonimmunized mouse and rabbit IgG remained negative.

In the biopsy sections stained for TRAP activity no multinucleate TRAP-positive osteoclasts were found in fibrous mesenchym infiltrating the degrading TCP particles or in the

Table 2
Summary of immunohistochemical evaluation of osteogenic marker expression in the cellular and matrix components of biopsies obtained from 20 patients in which TCP-C or TCP-CM was used as grafting material

Marker	Region	Graft material	Cellular components			Matrix components		
			Osteoblasts	Osteocytes	Fibroblasts	Fibrous matrix	Bone matrix	Osteoid
Col I	Apical	TCP-C	Moderate	Mild	Mild	Mild	Mild	Minimal
	Apical	TCP-CM	Moderate	No	Mild	Moderate	Moderate	No
	Significance			s ($p < 0.048$)		n.s.	n.s.	n.s.
	Central	TCP-C	Moderate	Mild	Minimal	Minimal	Mild	Minimal
	Central	TCP-CM	Mild	No	Mild	Moderate	Mild	Minimal
	Significance		n.s.	n.s.	n.s.	s ($p < 0.032$)		n.s.
ALP	Apical	TCP-C	Minimal	No	Minimal	Minimal	Minimal	Minimal
	Apical	TCP-CM	No	No	Mild	Mild	Mild	No
	Significance		n.s.		n.s.	n.s.	n.s.	n.s.
	Central	TCP-C	Minimal	No	Minimal	Minimal	Minimal	No
	Central	TCP-CM	No	No	No	Mild	Mild	Minimal
	Significance		n.s.		n.s.	s ($p < 0.031$)	n.s.	n.s.
OC	Apical	TCP-C	Strong	Minimal	Mild	Strong	Mild	Minimal
	Apical	TCP-CM	Moderate to strong	Minimal	Mild	Moderate	Moderate	Minimal
	Significance		n.s.			s ($p < 0.011$)	n.s.	
	Central	TCP-C	Moderate	Mild	Mild	Strong	Mild	Minimal
	Central	TCP-CM	Moderate	Minimal	Minimal	Moderate	Moderate	Minimal
	Significance			n.s.	n.s.	s ($p < 0.009$)	n.s.	
BSP	Apical	TCP-C	Moderate	Minimal	Mild	Strong	Mild	Minimal
	Apical	TCP-CM	Mild	Minimal	No	Moderate	Minimal	Minimal
	Significance		n.s.		s ($p < 0.041$)	n.s.	n.s.	
	Central	TCP-C	Moderate	Minimal	Mild	Strong	Mild	Minimal
	Central	TCP-CM	Moderate	Minimal	No	Moderate	Mild	No
	Significance				n.s.	n.s.		n.s.

An average score of (3.5–5), (2.3–3.4), and (1–2.2) corresponded to strong, moderate and mild expression, while an average score of (0.1–0.9) correlated with minimal and a score of (0) with no expression.

mineralized bone tissue in contact with the TCP particles (Fig. 9), while in the positive controls (experimental fracture healing sites) numerous multinucleate TRAP-positive cells were present.

4. Discussion

Ideally, a biomaterial used as bone substitute material should be a temporary material serving as a scaffold for bone formation. As such, it should undergo complete substitution by newly formed functional bone tissue [5,28]. Especially for applications such as alveolar ridge augmentation this substance must be relatively rapidly resorbable in view of placing implants in such augmented sites [4,5]. Bone bioactivity has been defined as the ability of materials to form a bond with the adjacent tissues [29,30]. Ideally, this bond consists of bone laid down by osteoblastic cells recruited to the implant surface. Consequently, bioactive bone substitute materials for use in alveolar ridge augmentation should posses the ability to activate bone formation in combination with a high degradation rate [4,5]. This in turn requires the ability to differentiate osteogenic cells into osteoblasts on their surface [13,30]. Differentiating osteoblasts synthesize and secrete alkaline phosphatase and bone matrix proteins such as type I collagen, osteocalcin, osteopontin and bone sialoprotein, which have proven to be particularly useful osteogenic markers characterizing the different stages of osteoblast differentiation [31,32].

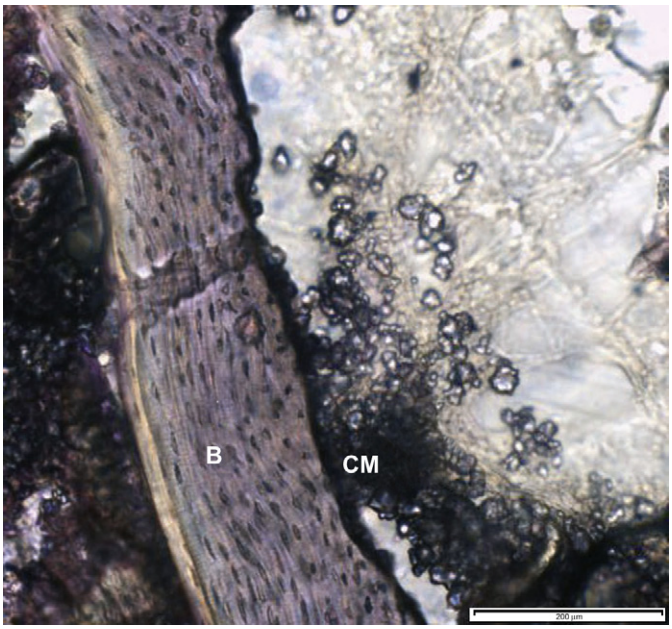

Fig. 9. Histomicrograph of deacrylated sawed section of biopsy sampled 6 months after augmentation of the sinus floor with TCP-CM (patient no. 14). The section was stained for Tartrate Resistant Acid Phosphatase (TRAP) activity to identify cells with osteoclastic activity. While newly formed lamellar bone (B) within the degrading particles (CM) is present, TRAP staining did not reveal any multinucleate cells with positive staining and osteoclastic activity. Bar = 200 µm.

Col I and ALP are characteristic of the early stages of osteoblast differentiation, whereas OC and BSP are characteristic of the terminally differentiated osteoblast, which is actively involved in extracellular-matrix mineralization [31,32]. Consequently, since there is no specific single marker for osteoblasts, the cellular expression of a range of bone matrix proteins as well as of alkaline phosphatase has to be investigated, when examining cellular differentiation and tissue maturation. Thus, the present study semi-quantitatively records the tissue response to two TCP bone substitute materials with varying porosity after sinus grafting in terms of protein expression of an array of osteogenic markers as a measure of phenotypic differentiation and tissue maturation. This is in addition to measuring the amount of bone formed as well as the residual graft material present after 6 months of implantation. The difference in porosity of the two TCP grafting materials affected bone formation, particle degradation as well as the expression of osteogenic markers in the newly formed tissue. In the current study, in the TCP-CM group greater bone formation and more enhanced staining for OC was noted in the mineralized bone matrix in the apical area compared to the TCP-C group. Expression of OC and BSP have been tightly linked to osteoid production and matrix mineralization [31,32], thereby suggesting that in the TCP-CM group bone formation and matrix mineralization had already reached a more advanced state compared to the TCP-C group, but was still progressing, since moderate expression of OC and BSP in the yet unmineralized fibrous matrix of the cell rich-osteogenic mesenchym was present. The TCP-C group showed strong OC and BSP staining of the unmineralized fibrous matrix components indicating that matrix mineralization and bone formation, although being less advanced than in the TCP-CM group, was strongly progressing at this stage. Furthermore, in both patient groups, positive Col I and ALP expression in the cellular and matrix components surrounding the residual grafting materials was demonstrated with only minor differences being noted between the TCP-CM and TCP-C group. These findings further confirm that at 6 months bone matrix synthesis and maturation was still actively progressing in both patient groups.

Taken together, the data of the immunohistochemical and histomorphometric analyses suggest that with both tricalcium phosphate graft materials bone formation and matrix mineralization were still actively progressing 6 months after augmentation of the sinus floor, while in the TCP-CM group bone formation and matrix mineralization had already reached a more advanced state compared to the TCP-C group. It is noteworthy that this significantly greater bone formation was recorded in the apical area close to the Schneiderian membrane, i.e., at the greatest distance from the original sinus floor, and was associated with a significantly higher particle degradation of the more porous TCP material in both the apical as well as the central area. In addition, good bone bonding behaviour as well as bone formation within the degrading particles was observed with both materials. Infiltration of the degrading particles with newly formed bone tissue was more advanced in TCP-CM group.

Furthermore, the fibrous mesenchym infiltrating the degrading TCP particles as well as the mineralized bone tissue in contact with the TCP particles lacked multinucleate TRAP-positive osteoclasts in both patient groups. This is suggestive that osteoclasts did not play a major role with respect to the degradation process of the particles and that both type of TCP particles degraded mainly by chemical dissolution.

Our observations are consistent with findings of Zerbo et al. [7,8] and Suba et al. [10] who evaluated biopsies, sampled from patients 6 months after augmentation of the sinus floor using Cerasorb™, i.e., TCP-C particles. Zerbo and associates demonstrated that these TCP particles supported bone regeneration [7,8] and had a stimulatory effect on osteoblastic differentiation [8]. Furthermore, it was shown that by 6 months TCP particles attracted osteoprogenitor cells that migrated into the interconnecting micropores of the bone substitute material [7,8]. These cells differentiated into osteoblasts and thus brought about bone deposition. The histologic data also indicated that the TCP particles degraded by chemical dissolution and that the role played by osteoclasts was only minor [8,10].

In our study, in both patient groups, the amount of bone regeneration achieved facilitated successful implant placement with no implant failures noted up to the completion of this manuscript (2–3 years after implant placement).

Studies on osteoblasts function indicate diminished osteoblast function in 45–65 year-old women, whereas osteoblast function of male donors of the same age was shown to be similar to that of young male and female patients (young: <30 years of age) [33]. In the current study, no meaningful differences were noted between the biopsies obtained from male and female patients belonging to this age group (45–65 years of age), although one might expect age related differences in a female population. This results from the fact that addressing age related issues controlled for gender requires a different sample size than the one employed in this study. This is an interesting question that remains to be addressed, and as such we have initiated a study, which compares biopsies among patients 45–65 years of age controlled for gender.

In recent years, there has been an ongoing search for predictable sinus grafting procedures, which utilize adequate bone substitute materials without the need to harvest autogenous bone so as to avoid donor site morbidity [4,5,8–10,34]. Consequently, recently several histological studies [8–10] compared the amount of bone formation after augmentation of the sinus floor with TCP particles alone to the amount formed after augmentation with autogenous bone, which was either harvested form the chin (bone chips) [8,9] or from the iliac crest (spongious bone) [9,10]. These clinical studies concluded that 6 months after sinus grafting the augmented sinus floor was sufficiently strong and suitable for anchorage of dental implants, irrespective of whether autogenous bone or TCP-C particles had been used [8,9]. It was noted, however, that the bone, which was formed in the TCP sites was less mature at 6 months [8]. In this context, it would be of great interest to elucidate, whether long-term clinical studies yielded differences in implant survival rates, an issue which remains to be addressed by future studies.

In our study, the amount of bone regeneration achieved facilitated successful implant placement without any implant failures in all patients irrespective of whether TCP-C or TCP-CM was used. The histomorphometric findings, however, showed a significantly greater amount of bone formation in the apical area in the TCP-CM group. Consequently, the current study demonstrates that the greater porosity of the TCP-CM material resulted in more enhanced bone regeneration in the apical area, i.e., at the largest distance from the crestal bone. These observations are in agreement with *in vitro* findings, which demonstrate a stimulating effect of the pore geometry of bone substitute materials on bone cell function and osteoblast differentiation [35]. In this context, it is also has to be noted that the greater bone formation and particle degradation, which was observed apically with the TCP-CM material, was not associated with any decrease in overall bone height of the augmented sinus floor 6 months after sinus grafting due to any resorptive processes.

In the present study, a combination (4:1 ratio) of TCP particles and autogenous bone chips was used for augmenting the sinus floor. In view of the encouraging findings of the clinical studies cited above [7–10], in which TCP-C particles alone were used for sinus floor augmentation, it will be of interest to elucidate in future clinical studies whether the same results as reported in our present study can be achieved when using TCP particles alone.

Furthermore, our findings which demonstrated that in the TCP-CM group bone formation and matrix mineralization had already reached a more advanced state at 6 months compared to the TCP-C group, raise the question whether the use of the more porous TCP-CM particles may facilitate implant placement at an earlier time point, i.e., 4–5 months after sinus augmentation. This is an interesting question of high clinical relevance which remains to be addressed in view of the overall efforts in implant dentistry to develop treatment protocols, which allow for shorter treatment times. As a result, this issue is currently addressed at a first level by an animal study, in which TCP-CM particles alone were used in sheep for augmentation of the sinus floor. The augmented sites were harvested 1, 3 and 6 months after implantation of the grafting material. Histomorphometric evaluation of the histological sections is currently underway.

5. Conclusions

Both TCP materials supported bone formation in the augmented sinus floor. Six months after implantation of both types of β-TCP particles, bone formation and matrix mineralization was still actively progressing in the tissue surrounding the particles. In the TCP-CM patient group, bone formation and particle degradation had already reached a more advanced stage at 6 months. Consequently, a greater porosity of these particles appears to be advantageous for enhancing bone formation and particle degradation.

Acknowledgements

This work was funded by the German Research Foundation (DFG grant no. KN 377/3-1). The authors wish to thank Ms. Annekathrin Kopp and Mrs. Ines Borchert for their excellent technical assistance and expertise. The authors gratefully acknowledge Dr. Larry Fisher (NIDCR, Bethesda, Maryland, U.S.A.) for providing the polyclonal antibodies used in this study. Furthermore, the authors are particularly thankful to Dr. Herbert Renz for his excellent help with the digital imaging and the SIS Analysis™ software.

Appendix A. Supplementary data

Supplementary data associated with this article can be found, in the online version, at doi:10.1016/j.biomaterials.2008.01.026.

References

[1] Belser UC, Mericske-Stern R, Bernard JP, Taylor TD. Prosthetic management of the partially dentate patient with fixed implant restorations. Clin Oral Implants Res 2000;11(Suppl. 1):126–45 [Review].
[2] Winkler S. Implant site development and alveolar bone resorption patterns. J Oral Implantol 2002;28:226–9.
[3] Buser D, Dula K, Hess D, Hirt HP, Belser UC. Localized ridge augmentation with autografts and barrier membranes. Periodontol 2000 1999;19:151–63 [Review].
[4] Zijderveld SA, Zerbo IR, van den Bergh JP, Schulten EA, ten Bruggenkate CM. Maxillary sinus floor augmentation using a β-tricalcium phosphate (Cerasorb) alone compared to autogenous bone grafts. Int J Oral Maxillofac Implants 2005;20:432–40.
[5] Wheeler SL. Sinus augmentation for dental implants: the use of alloplastic materials. J Oral Maxillofac Surg 1997;55:1287–93 [Review].
[6] Kalk WW, Raghoebar GM, Jansma J, Boering G. Morbidity from iliac crest bone harvesting. J Oral Maxillofac Surg 1996;54:1424–9.
[7] Zerbo IR, Zijderveld SA, de Boer A, Bronckers AL, de Lange G, ten Bruggenkate CM, et al. Histomorphometry of human sinus floor augmentation using a porous β-tricalcium phosphate: a prospective study. Clin Oral Implants Res 2004;15:724–32.
[8] Zerbo IR, Bronckers AL, de Lange G, Burger EH. Localisation of osteogenic and osteoclastic cells in porous β-tricalcium phosphate particles used for human maxillary sinus floor elevation. Biomaterials 2005;26:1445–51.
[9] Szabo G, Huys L, Coulthard P, Maiorana C, Garagiola U, Barabas J, et al. A prospective multicenter randomized clinical trial of autogenous bone versus β-tricalcium phosphate graft alone for bilateral sinus elevation: histologic histomorphometric evaluation. Int J Oral Maxillofac Implants 2005;20:371–81.
[10] Suba Z, Takacs D, Matusovits D, Barabas J, Fazekas A, Szabo G. Maxillary sinus floor grafting with β-tricalcium phosphate in humans: density and microarchitecture of the newly formed bone. Clin Oral Implants Res 2006;17:102–8.
[11] Peters F, Reif D. Functional materials for bone regeneration from β-tricalcium phosphate. Materwiss Werksttech 2004;35:203–7.
[12] Buser D, Hoffmann B, Bernard JP, Lussi A, Mettler D, Schenk RK. Evaluation of filling materials in membrane-protected bone defects. A comparative histomorphometric study in the mandible of miniature pigs. Clin Oral Implants Res 1998;9:137–50.
[13] Ducheyne P, Qiu Q. Bioactive ceramics: the effect of surface reactivity on bone formation and bone cell function. Biomaterials 1999;20:2287–303 [Review].

[14] Knabe C, Berger G, Gildenhaar R, Meyer J, Howlett CR, Markovic B, et al. The effect of rapidly resorbable calcium phosphates and a calcium phosphate bone cement on the expression of bone-related genes and proteins in vitro. J Biomed Mater Res 2004;69A:145–54.
[15] Knabe C, Berger G, Gildenhaar R, Howlett CR, Markovic B, Zreiqat H. The functional expression of human bone-derived cells grown on rapidly resorbable calcium phosphate ceramics. Biomaterials 2004; 25:335–44.
[16] Roeser K, Johansson CB, Donath K, Albrektsson T. A new approach to demonstrate cellular activity in bone formation adjacent to implants. J Biomed Mater Res 2000;51:280–91.
[17] El-Ghannam A, Ducheyne P, Shapiro IM. Formation of surface reaction products on bioactive glass and their effects on the expression of the osteoblastic phenotype and the deposition of mineralized extracellular matrix. Biomaterials 1997;18:295–303.
[18] Zreiqat H, Markovic B, Walsh WR, Howlett CR. A novel technique for quantitative detection of mRNA expression in human bone derived cells cultured on biomaterials. J Biomed Mater Res B Appl Biomater 1996; 3:217–23.
[19] Neo M, Herbst H, Voigt CF, Gross UM. Temporal and spatial patterns of osteoblast activation following implantation of β-TCP particles into bone. J Biomed Mater Res 1998;39:71–6.
[20] Ohsawa K, Neo M, Matsuoka H, Akiyama H, Ito H, Kohno H, et al. The expression of bone matrix protein mRNAs around β-TCP particles implanted into bone. J Biomed Mater Res 2000;52: 460–6.
[21] Knabe C, Kraska B, Koch C, Gross U, Zreiqat H, Stiller M. A method for immunohistochemical detection of osteogenic markers in undecalcified bone sections. Biotech Histochem 2006;81:31–9.
[22] Tatum HJ. Maxillary and sinus implant reconstructions. Dent Clin North Am 1986;30:207–29.
[23] Fisher LW, Stubbs 3rd JT, Young MF. Antisera and cDNA probes to human and certain animal model bone matrix noncollagenous proteins. Acta Orthop Scand Suppl 1995;266:61–5.
[24] Goldberg AF, Barka T. Acid phosphatase activity in human blood cells. Nature 1962;189:297.
[25] Farhadieh RD, Gianoutsos MP, Yu Y, Walsh W. The role of bone morphogenetic proteins BMP-2 and BMP-4 and their related postreceptor signaling system (Smads) in distraction osteogenesis of the mandible. J Craniofac Surg 2004;15:714–8.
[26] Tavakoli K, Yu Y, Shahidi S, Bonar F, Walsh WR, Poole MD. Expression of growth factors in the mandibular distraction zone: a sheep study. Br J Plast Surg 1999;52:434–9.
[27] Knabe C, Nicklin S, Yu Y, Walsh WR, Radlanski RJ, Marks C, et al. Growth factor expression following clinical mandibular distraction osteogenesis in humans and its comparison with existing animal studies. J Craniomaxillofac Surg 2005;33:361–9.
[28] Yaszemski MJ, Payne RG, Hayes WC, Langer R, Mikos AC. Evolution of bone transplantation: molecular, cellular and tissue strategies to engineer human bone. Biomaterials 1996;17:175–85 [Review].
[29] Hench LL. Bioactive glasses, ceramics, and composites. Bone-Implant Interface 1994;9:181–90 [Review].
[30] Ohgushi H, Okumura M, Tamai S, Shors EC, Caplan AI. Marrow cell induced osteogenesis in porous hydroxyapatite and tricalcium phosphate: a comparative histomorphometric study of ectopic bone formation. J Biomed Mater Res 1990;24:1563–70.
[31] Sodek J, Cheifitz S. Molecular regulation of osteogenesis. In: Davies JE, editor. Bone engineering. Toronto, Canada: em squared Inc.; 2000. p. 31–43.
[32] Aubin JE. Osteogenic cell differentiation. In: Davies JE, editor. Bone engineering. Toronto, Canada: em squared Inc.; 2000. p. 19–30.
[33] Zhang H, Lewis CG, Aronow MS, Gronowicz GA. The effects of patient age on human osteoblasts' response to Ti-6Al-4V implants in vitro. J Orthop Res 2004;22:30–8.
[34] Artzi Z, Kozlovsky A, Nemcovsky CE, Weinreb M. The amount of newly formed bone in sinus grafting procedures depends on tissue depth as well as the type and residual amount of the grafted material. J Clin Periodontol 2005;32:193–9.
[35] Yao J, Radin S, Leboy PS, Ducheyne P. Solution mediated effect of bioactive glass in poly (lactic-co-glycolic acid) – bioactive glass composites on osteogenesis of marrow stromal cells. J Biomed Mater Res A 2005;75:794–801.